

*Research Article***Comparative study between role of flexible IMN and hip spica in femoral shaft fracture in children****Sherif Abdelmoneim El-Tregy**

Department of Orthopedic, Banha Faculty of Medicine

**Abstract**

**Background:** Pediatric femoral shaft fractures management have Various nonoperative and operative modalities. **Methods:** This prospective study was held on 40 patients with fracture shaft femur; 20 patients treated by hip spica and 20 patients treated by elastic rods. **Results:** In a prospective cohort study we managed 40 cases of closed femoral shaft fractures in children during the sixth year of their lives (5-6 year) by closed reduction and hip spica (20 patients) and by intramedullary nails (20 patients). Comparing the results of both techniques we found that intramedullary fixation technique to be associated with trivially longer hospital stay (1-2 days), higher incidence of infection (5% versus 0%), lower recovery of range of motion by time of complete healing ( $129 \pm 5$  versus  $132 \pm 4$  measured in degrees) shorter time to heal ( $45 \pm 15$  versus  $55 \pm 20$  days), walk with aids ( $25 \pm 7$  versus  $55 \pm 10$  days), walk independently ( $45 \pm 12$  versus  $60 \pm 10$  days) and less incidence of malalignment (0% versus 5% respectively). **Conclusion:** intramedullary elastic rods in five and six years old children in our study and in other studies has achieved good results in comparison to hip spica cast mostly for its capability of allowing early mobilization, weight bearing and return to full activities early.

**Keywords:** flexible IMN, hip spica, shaft fracture, and children**Introduction**

Pediatric femoral shaft fractures are relatively uncommon, representing less than 2% of all fractures in pediatric age group. Yet, they have a significant burden on healthcare providers being the most common fractures to require hospitalization in that group<sup>[1,2]</sup>. Requiring prolonged immobilization in a hip spica or surgery, they are well known to cause significant disruption of normal life as addressed by patients' families<sup>[1]</sup>.

They tend to unite rapidly and have a tremendous remodeling potential. Consequently, a wide range of deformity of the initial healed bone is considered acceptable.<sup>[2]</sup>

A wide range of variables guide the decision to manage a femoral shaft fracture by conservative or operative means which include patient's age and weight, the pattern of fracture, associated injuries and expected compliance of the caregivers at home<sup>[3]</sup>.

Age is virtually defined as the main determinant of the treatment most appropriate option. Below 5 years of age, such injuries are usually

managed conservatively due to the remarkable remodeling potential at this age. Various non-operative modalities are used including Pavlik harness in children younger than 6 months of age, traction methods, hip Spica and functional bracing.<sup>[3]</sup>

The optimal method for treatment of fractures at the age of six year is still debatable, with multiple options available and no clear agreement on the supposedly better modality of management. Surgical options include external fixation, plating and intramedullary nails which can be by flexible nails (titanium nail, Enders nail) or rigid pediatric nails<sup>[3]</sup>.

**The aim of this study** was to compare between outcomes of use of flexible IMN versus hip Spica in treatment of fracture femur in children from 5 to 6 years old.

**Patients and methods**

This prospective study was held on 40 patients with fracture shaft femur; 20 patients treated by hip spica and 20 patients treated by elastic rods at Benha university hospitals from the period 2018 to 2020 Children aged 5 to 6 years old

with isolated closed femoral shaft fracture were included in the study. Any patient with incomplete x-ray documentation, open fractures, neurovascular compromise, pathological fractures, metaphyseal and epiphyseal fractures, and unfit patient for surgery were excluded from the study.

There was no statistical significant difference between both groups regarding age, gender, side or mechanism of injury. Table 1 demonstrates the patients' demographics in both groups. The patients included in the study were 26 boys and 14 girls. In group of spica cast 16 boys and 4 girls, in group of elastic rods 12 boys and 8 girls. The right side was affected in 24 patients (9 in spica group, 15 in nail group), while the left side was affected in 16 patients (11 in spica group, 5 in nail group). All the patients included in the study were evaluated by history taking (from the patient and their parents, including the date of the injury and the details of the initial and subsequent treatment), general and local examination (especially to the neurovascular status). Radiographic evaluation included plain X-ray antero-posterior and lateral views of femur from hip to knee.

#### **Spica cast technique:**

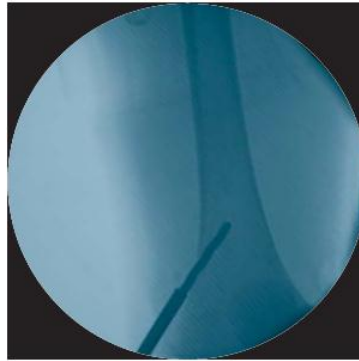
Closed reduction was done under sedation or general anesthesia. Hips were flexed 60-90° and were placed in approximately 30° of abduction, and knees were placed in 45° of flexion. External rotation was typically needed to correct rotational deformity. Mold along the distal femoral condyles and buttocks was done to maintain reduction. The goal of reduction should include obtaining < 10° of coronal plane and < 20° of sagittal plane deformity with no more than 2cm of shortening or 10° of rotational malalignment. Flexion-deflexion technique was required for correction of transverse and short oblique fractures with gross shortening. Check radiographs were typically taken on image intensifier before application of the cast to ensure acceptable reduction.

#### **Flexible intramedullary nail technique (figure 1, 2 and 3 )**

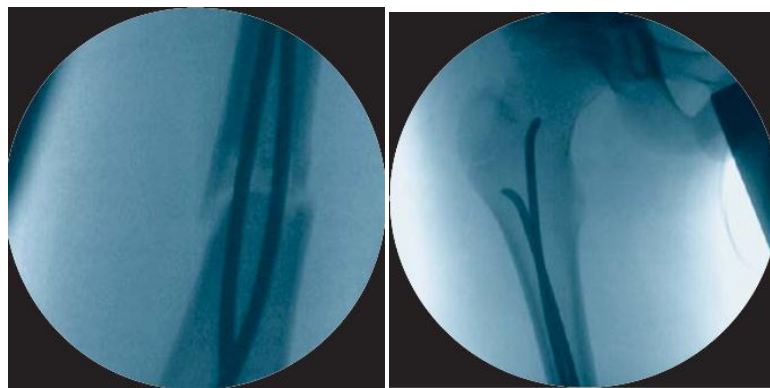
Either standard fracture table or tables with traction devices were used. The patient lies supine. Preliminary reduction had been attempted and alignment was confirmed with fluoroscopy before the limb is prepared and draped from hip to foot with the leg free for traction and manipulation. Nail contour adjustment was done either manually or using bending devices. Proper contouring should address both nails to have similar contours into bow shape.

Skin incisions (medial and lateral) were placed 3 cm above distal femoral physis as confirmed with fluoroscopy and were 3 cm long. The femoral cortex was opened using a drill bit or an Awl. After penetrating the near cortex at almost right angle, the drill bit should be redirected, while still rotating (this prevents its breakage, at 45 degrees angle to the femoral axis creating an oblique hole. Care must be taken for the drill bit or the Awl not to slip especially posteriorly when working on the medial side as the femoral artery is at risk in this region.


During nail insertion, the nail tip was directed with the convex side to slide over or better move away from the inner side of the far cortex. The nail was advanced by using a Slide Hammer and a guide to control its pathway being tracked through the bone. The first nail was advanced to the level of the fracture. In a similar fashion the same procedure was repeated for the second nail. Closed reduction was achieved in all cases except two cases needed open reduction. The first nail was advanced only enough to maintain fracture reduction and prevent its displacement then the second nail was advanced. After passage through the fracture, both nails were sequentially advanced to final position after cutting the distal ends of each to proper length and verification of reduction including rotation and stability.



**Figure (1) Opening the distal femur (3)**



**Figure (2) Insertion of nails and crossing the fracture up to a final position (3)**



**Figure (3) Final advancement and fluoroscopy check (3)**

**Follow up**

Clinical examination was done for assessment of any complications till complete bone healing, and disappearance of pain, full weight bearing as well as Knee full ROM. Radiological evaluation included AP and Lat. Radiographs

by serial x-rays every week for 2 months. Any residual complications as non-union, gross deformity in sagittal or frontal plane or rotational deformity as well as leg length discrepancy were recorded.

## Results

Full union was achieved in all cases (table1 )

**Table (1) Patients outcomes**

Variables	Hip spica	ER	P value
Hospital stay (days)	2 ± 1	1±1	0.0017
Walking with aids (days)	25 ± 7	55 ± 10	0.15
Walking independently(days)	45 ± 12	60 ±10	0.19
Union (mean in months ± SD)	1.65 ± 0.49	1.73 ± 0.79	0.91

The spica cast group was found to have a shorter duration of hospital stay compared with elastic nail group This was explained by the time required for preparing patients for surgery and postoperative management. There was no significant difference between patients treated operatively, regarding closed versus open reduction, when related to this variant. The knee range of motion of the spica cast group ( $132^{\circ} \pm 4$ ) at the final follow up (mean time 55 days) was found to be better compared with the elastic rods group ( $129^{\circ} \pm 5$ )

The elastic nailing group was found to have started walking earlier both with and without support. Patients with intramedullary nailing started to walk with aid after one month ( $25 \pm 7$  days) and independently after 2 months ( $45 \pm 12$  days) Patients with spica cast started to walk with aid after 2 months ( $55 \pm 10$  days) and independently after 3months ( $60 \pm 10$  days).

The clinical measurement of patients' limb length discrepancy was within the acceptable limits in both group (mean, range in both groups).

One patient developed superficial infection with implant irritation on the incision site that was managed conservatively by antibiotics and daily dressing. irritation was completely relieved after removal of the nails following complete union.

When the groups compared, the spica cast group was found to have a shorter duration of

hospital stay ( $1 \pm 1$ ) compared with elastic nail group ( $2 \pm 1$ ). This was explained by the time required for preparing patients for surgery and postoperative management. There was no significant difference between patients treated operatively, regarding closed versus open reduction, when related to this variant.

The knee range of motion of the spica cast group ( $132^{\circ} \pm 4$ ) at time of full union (mean time 55 days) was found to be better compared with the elastic rods group ( $129^{\circ} \pm 5$ ).

The elastic nailing group was found to have started walking earlier both with and without support. Patients with intramedullary nailing started to walk with aid after one month ( $25 \pm 7$  days) and independently after 2 months ( $45 \pm 12$  days) Patients with spica cast started to walk with aid after 2 months ( $55 \pm 10$  days) and independently after 3months ( $60 \pm 10$  days).

The clinical measurement of patients' limb length discrepancy was within the acceptable limits in both group. No malrotation could be detected in any of the patients in both groups.

One superficial infection with implant irritation developed on the incision site in one patient of the operative group which was managed conservatively by antibiotics and daily dressing, as regarding infection, while irritation was completely relieved only after removal of the nails following complete union.

Malalignment was detected in one (5%) patients as complication in spica cast group,

and none (0%) was detected as complication in intramedullary nailing.

Although we had no certain questionnaire planned to collect certain data we could, throughout our study make some, unfortunately, undocumented relations to social, economic and educational variants regarding patients' families. Although femoral shaft fractures are overall are considered a devastating interruption to patients' families life styles, yet Intramedullary nailing has psychological, social, educational, and some

economical advantages over hip spica. Caregivers found difficulties in dealing with the spica cast, though most of those whose children were treated in that manner had preferred it to surgery. Most of these caregivers were noted not to have attended any form of higher education while families with higher socioeconomic and educational standards found surgery a more convenient option and were eventually found to have more satisfaction rates especially during recovery process not only after it.

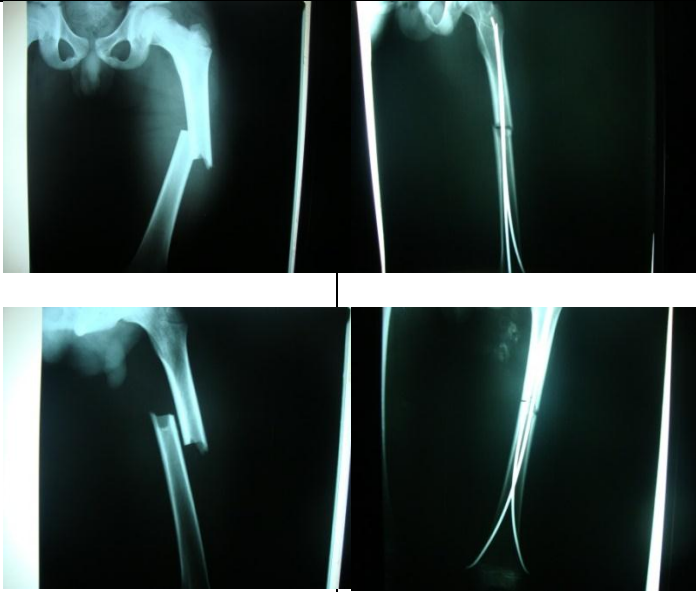
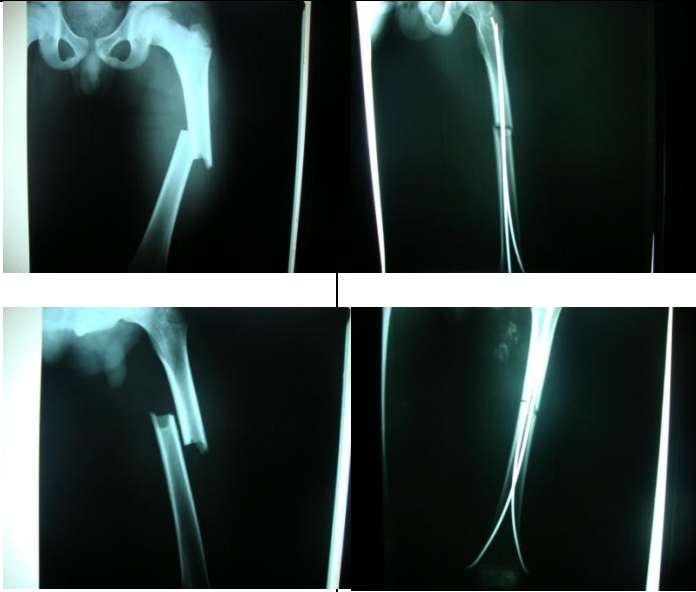
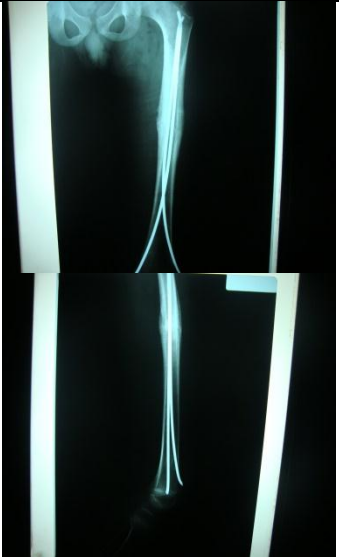
Patient	preoperative	Immediate after fixation	Union and timing
Male			

Table (2) cases example elastic nails.




Age	pre cast x rays	Post cast x rays	
60 M Male Rt Fog			

Table (3) cases managed by hip spica

## Discussion

The best method of treating femoral shaft fractures in the pediatric age group (5 to 6 years old) is still a matter of debate. Despite the enormous amount of literature focused on naming such technique, the multifactorial nature of that decision seems to require a system taking in consideration those factors rather than naming single option to be the best, even for a namely pattern or a specified age.<sup>(2)</sup> These factors include pattern of fracture, associated injuries and surgical experience. Some other factors are growingly brought into focus such as weight of the patient or more specifically body mass index and neurological status of the patient.<sup>(3)</sup>

Despite the increase in surgical treatment choices, with the increase in fixation techniques and improved imaging methods, the basic rules described for the treatment for pediatric femoral fractures remain valid today. These basic rules as described by Dameron and Thompson<sup>(4)</sup> are: The simplest treatment is best, The initial treatment should be permanent where possible, Perfect anatomic reduction is not essential for perfect function, Restoration of alignment is more important than fragment position, Over treatment is usually worse than under treatment, and Immobilize/splint the injured limb before definitive treatment.

In a network meta-analysis, Zhao et al., defined four techniques to be used in treatment of pediatric femoral shaft fractures. Actually, although rarely used for very specific indications, there are a few more options. But generally it is widely accepted that these four techniques are the main methods to be considered in any study tended to be practically relevant. They are cast, plate fixation, titanium elastic nail and external fixation.<sup>(5)</sup>

In this Bayesian network metaanalysis, the results indicated that titanium elastic nails could significantly reduce the ankylosis, malunion rates and union time. Furthermore, they also had the lowest infection rate among all surgical treatments. In recent years, a large number of studies have also confirmed the effectiveness of titanium elastic nails in the treatment of pediatric femoral shaft fractures<sup>(6,7,8)</sup>

In our practice we noticed a grey zone at the age of 5-6 years age group which was included in some recommendations as preschool age that

should be treated with hip spica whenever close fractures encountered while others recommended treating that group using the same methods of older than 6 years of age patients. Some even went further dividing patients to 2 groups of younger and older than 4 years of age.<sup>(9)</sup> It seems that we were not the only observers who spotted that grey zone. In their clinical practice guidelines, the American Academy of Orthopedic Surgeons recommended this age group<sup>(5-6)</sup> to be furtherly investigated regarding the use of flexible nails against hip spica while treating femoral shaft fractures, and in even younger age.<sup>(10)</sup>

Immediate hip spica was the most appropriate method of treatment was the overall accepted method for treating femoral shaft fractures in children younger than 5 years, not that it is complications free, but the results were constantly satisfactory. The most significant, though fortunately not the most common, complications were loss of reduction necessitating revision under general anaesthesia, malunion prolonged immobilization that caused delayed return to normal activities, when compared to nailing, and in very few incidents compartment syndrome.<sup>(2,3,4)</sup>

The care for the child in spica is particularly troublesome in our experience, the socio-economic and psychological burden that having a kid with a hip spica being treated and followed up, with the ongoing potential of developing complications especially during the first three weeks of treatment, can be significantly not tolerated by certain families. Some serious skin complications can take place with less compliant caregivers. Although no serious skin problems was met during our study but we surely were faced by some minor ones that necessitated prompt management, part of which was emphasizing the importance of skin care to parents, to halt the progression of such conditions.

External fixators have some advantages such as simplicity of application and suitability to ages as young as 3 years. However complications like pin tract infection, sometimes causing septic shock, limitation of knee motion ugly scars, need for post-removal casting and 21% refracture rate make their usage often limited to open fractures and to a lesser extent to poly-

traumatized patients.<sup>(11)</sup> Regarding rigid intramedullary nailing, high rate of avascular necrosis of femoral head and coxa valga make them an obsolete choice in preschool age group. Elastic stable intramedullary nailing was introduced by Pre´vot et al., in 1979<sup>(12)</sup>, utilizing the three-point fixation principle. The technique offers good reduction, dynamic axial stabilization, and early rehabilitation. However, it has many disadvantages, such as length discrepancy, rotational malalignment, malunion, nail exteriorization, and interference with knee motion by the prominent nail ends.

In our study the use of ER provide good union rate and early range of motion but has complication as skin irritation in 6 cases and superficial infection in 1 case. In our study we found elastic intra medullary nailing to be associated, when compared with immediate hip spica) with shorter time to full union (especially when done using only percutaneous technique) and walking with and without aids. Incidence of malunion was lower with intramedullary group. Length stable fractures did not need additional external restraining and made early weight bearing possible especially in children weighing less than 50 kilograms. Length unstable fractures were significantly correlated to shortening, slower union and overgrown callus (which did not reach clinical significance) and frequently required post-operative additional casting and deferred weight bearing till full radiographic consolidated union was achieved.

These findings as well as our surgical time, switching to open reduction, time to union, incidence of painful nail ends, hospital stay and time to nail removal are more or less aligned with literature comparing the same techniques in the same age group inspite of the fact that they included that group as a part of studying larger groups. Moreover, although not subjected to a specified measurement or questionnaire, families of patients treated using intramedullary nails we more complacent about their whole fracture experience.

Skin irritation can be severe enough to make second surgery for managing excessively long ends of the nail necessary. This is a completely avoidable situation through careful use of the nail length and more importantly proper insertion and trimming of the nail.

This minimally invasive technique requires short hospital stay compared to other methods of surgical and some conservative treatment, and it has been proven that it can be done with minimum hospital stay, as most children can be readily discharged on the same day of surgery.<sup>(10,13,14)</sup>

Although we had no certain questionnaire planned to collect certain data we could, throughout our study make some, unfortunately, undocumented relations to social, economic and educational variants regarding patients' families. Although femoral shaft fractures are overall are considered a devastating interruption to patients' families life styles, yet Intramedullary nailing has psychological, social, educational, and some economical advantages over hip spica. Caregivers found difficulties in dealing with the spica cast, though most of those whose children were treated in that manner had preferred it to surgery. Most of these caregivers were noted not to have attended any form of higher education while families with higher socio-economic and educational standards found surgery a more convenient option and were eventually found to have more satisfaction rates especially during recovery process not only after it .

It combines the best characteristics of closed treatment methods (preservation of the biology of the fracture site) with the best characteristics of surgical treatment (stability and preservation of the correct alignment, early mobility and ease of care).in our study we did 19 cases through closed reduction and only one case through open reduction which delayed time of full union.

Preschool children constituted a small number of patients treated in many series. The children studied were treated using the one-surgeon–one-technique approach, which would give a better assessment of the results.<sup>(15)</sup>

Aktekin et al., in 2007 concluded that elastic nails should be the treatment of choice in school age group.<sup>(16)</sup> Singh et al., in 2006 and Saikia et al., 2007 considered elastic nails as the ideal implant for pediatric femur fractures<sup>(17)</sup> Houshian et al., in 2004 considered elastic nailing to be a safe method for the treatment of femoral shaft fractures in children between 4-11 years<sup>(18)</sup> M Manjunath et al., (2019) considered closed reduction and percutaneous nails to be

capable of managing such injuries with low incidence of complications in a similar age group to our study<sup>(19)</sup> Michael J. Heffernan et al., (2015) made conclusions of shorter time to independent ambulation and early return to full activity among children treated by elastic nails.<sup>(20)</sup> BV Lokesh et al., (2019) indicated that, with proper technique and choice of patients, complications can be avoided and satisfactory outcomes can be attributed to using elastic intra medullary rods in pediatric femoral shaft fractures.<sup>(21)</sup>

Pooja Pradeep Surawala and Venkatachalam K (2019), Chirag Prajapati et al., (2019), Raj Kumar et al., (2018), Seyed Abdolhossein et al., (2008), John M. Flynn et al., (2004) and concluded that in pediatric femur fractures in school age elastic rods are more capable of managing different patterns of fractures with less complications and earlier weight bearing and return to normal activity<sup>(22,23,24,25,26,27)</sup> especially in length stable femoral shaft fractures. Fracture femur in children treated with hip spica has chance of malalignment<sup>(28)</sup>

### Conclusion

intramedullary elastic rods in five and six years old children has good results in comparison to hip spica cast due to their capability of allowing early mobilization, weight bearing and return to full activities early. however, further studies are recommended concentrating on the same age group of this study with larger sample size, more specifications regarding patient weight, family satisfaction, through a questionnaire, and level of education of the caregiver as a measure of their anticipated compliance to skin care which was a continuous threat to the success of casted cases and relating it to the incidence of skin complications.

### Recommendations

we recommend further studies concentrating on the same age group of this study with larger sample size, more specifications regarding patient weight, family satisfaction, through a questionnaire, and level of education of the caregiver as a measure of their anticipated compliance to skin care which was a continuous threat to the success of casted cases and relating it to the incidence of skin complications.

### References

- 1- Flynn JM, Skaggs D. Femoral shaft fractures. In: Flynn JM, Skaggs D, Waters P, Eds. Rockwood & Wilkins' Fractures in Children. Philadelphia: Wolters Kluwer 2014; pp. 987-1026
- 2- Loder RT, O'Donnell Pw and Feinberg JR. Epidemiology and mechanisms of femur fractures in children. J Pediatric Orthop 2006; 26(5): 561-6
- 3- The Titanium Elastic Nail System Technique Guide Original Instruments and Implants of the Association for the Study of Internal Fixation—AO ASIF
- 4- Dameron TB JR and Thompson HA. Femoral-shaft fractures in children. Treatment by closed reduction and double spica cast immobilization. J Bone Joint Surg Am. 1959 Oct;41-A:1201-12.
- 5- Zhao Chen, Dawei Han, Qingyu Wang and Lianghua Li. Four interventions for pediatric femoral shaft fractures: Network meta-analysis of randomized trials International Journal of Surgery, 80, 2020; 53-60
- 6- Q.Z. Wu, J. Zhang, S.H. Lan [Clinical outcomes of elastic intramedullary nail fixation and external fixation for the treatment of pediatric femoral shaft fractures] Zhong Guo Gu Shang, 24(2) (2011), pp. 146-148
- 7- H.R. Song, C.W. Oh, H.D. Shin, S.J. Kim, H.S. Kyung, S.H. Baek, et al., Treatment of femoral shaft fractures in young children: comparison between conservative treatment and retrograde flexible nailing J. Pediatr. Orthop. B, 13(4)(2004), pp. 275-280
- 8- K. Aktuglu, N. Ozkayin [Long-term results of elastic intramedullary nailing in pediatric femoral shaft fractures] Ulus Travma Acil Cerrahi Derg, 9(3) (2003), pp. 203-208
- 9- Frank Melisie I, Egbert Krug, Jan W Duijff, Pieta Krijnen, Inger B Schipper [Age-specific treatment of femoral shaft fractures in children] Ned Tijdschr Geneesk 2012; 156(12): A3976.
- 10- The American Academy of Orthopaedic Surgeons Board of Directors, Treatment of Pediatric Diaphyseal Femur Fracture—evidence-Based Clinical Practice Guideline J, 2015, AAOS v1.0 061909
- 11- Domb BG, Sponseller PD, Ain M and Miller NH. Comparison of dynamic versus



- static external fixation for pediatric femur fractures. *J Pediatr Orthop*. 2002 Jul-Aug; 22(4):428-30.
- 12- Prévot J, Lascombes P et al., Elastic stable intramedullary nailing of femoral shaft fractures in children. *J Bone Joint Surg Br*. 1988 Jan; 70(1):74-7
  - 13- Miner T and Carroll KL. Outcomes of External Fixation of Pediatric Femoral Shaft Fractures. *Journal of Pediatric Orthopaedics*. 2000; 20(3):405-410.
  - 14- Hedequist D, Bishop J, Hresko T (2008) Locking plate fixation for pediatric femur fractures. *J Pediatr Orthop* 28:6-9.
  - 15- Ramseier LE, Janicki JA, Weir S, Narayanan UG (2010) Femoral fractures in adolescents: a comparison of four methods of fixation. *J Bone Joint Surg Am* 92: 1122-1129.
  - 16- Aktekin CN, Oztürk AM, Altay M, Toprak A, Ozkurt B and Tabak AY. Flexible intramedullary nailing of children. *Ulus Travma Acil Cerrahi Derg* 2007; 13(2): 115-21. [PMID: 17682953]
  - 17- Singh R, Sharma SC, Magu NK and Singla A. Titanium elastic nailing in pediatric femoral diaphyseal fractures. *Indian J Orthop* 2006; 40(1):29-34. [<http://dx.doi.org/10.4103/0019-5413.34071>]
  - 18- Houshian S, Gøthgen CB, Pedersen NW and Harving S. Femoral shaft fractures in children: elastic stable intramedullary nailing in 31 cases. *Acta Orthop Scand* 2004; 75(3): 249-51. [<http://dx.doi.org/10.1080/00016470410001150>][PMID: 15260414]
  - 19- Dr. M Manjunath, Dr. Syed Umer, Dr. Akshay Dhanda and Dr. Neelangowda V Patil (2019). A prospective study on the functional and radiological outcome of paediatric shaft of femur fractures treated with TENS nailing: A case series of 22 cases *National Journal of Clinical Orthopaedics* 2019; 3(3): 28-32
  - 20- Michael J. Heffernan, MD and et al., (2015) Treatment of Femur Fractures in Young Children: A Multicenter Comparison of Flexible Intramedullary Nails to Spica Casting in Young Children Aged 2 to 6 Years (*J Pediatr Orthop* 2015; 35:126-129).
  - 21- Dr. BV Lokesh, Dr. Ranganath Babu K, Dr. Srinivas R, Dr. Ashok Kumar Reddy and Dr. Sujai S, (2019). Evaluation of pediatric femoral shaft fractures managed with intra-medullary titanium elastic nails [TENS]: A prospective study *International Journal of Orthopaedics Sciences* 2019; 5(3): 397-401
  - 22- Dr. Pooja Pradeep Suratwala and Dr. Venkatachalam K (2019). Surgical management of fracture shaft of femur in children aged between 5 to 16 years using elastic stable intramedullary nailing *International Journal of Orthopaedics Sciences* 2019; 5(3): 402-410
  - 23- Dr. Chirag Prajapati, Dr. Nikunj Maru and Dr. Vipul Makwana (2019) Retrospective study of operative (Rush pin) versus conservative (Hip spica) management in treatment of diaphyseal femoral fractures in children *National Journal of Clinical Orthopaedics* 2019; 3(2): 30-34
  - 24- Raj Kumar, Anupma Kumari and Abhishek Pandit (2018). Evaluation of outcome of titanium elastic nailing (TEN) versus hip spica cast in the treatment of femoral shaft fractures in children *International Journal of Orthopaedics Sciences* 2018; 4(4): 149-154
  - 25- Seyed Abdolhossein Mehdinasab, Seyed Ali Marashi Nejad and Nasser Sarrafan (2008). Short Term Outcome Of Treatment Of Femoral Shaft Fractures In Children By Two Methods: Traction Plus Casting, Versus Intramedullary Pin Fixation – A Comparative Study *Pak J Med Sci* January - March 2008 Vol. 24 No. 1 147-151
  - 26- John M. Flynn, MD and I Ael M. Luedtke MD and et al., (2004). Comparison of Titanium Elastic Nails with Traction and a Spica Cast to Treat Femoral Fractures in Children *THE Journal Of Bone & Joint Surgery*. JBJS. Org Volume 86-A. No. 4. April 2004
  - 27- Yasser M. Assaghir (2012). Titanium elastic nail in femur fractures as an alternative to spica cast in preschoolers *J Child Orthop* (2012) 6:505-511